

# Improvement of masticatory kinematic parameters after correction of unilateral posterior crossbite: *Reasons for functional retention*

Maria Grazia Piacino<sup>a</sup>; Maria Cordero-Ricardo<sup>b</sup>; Rosangela Cannavale<sup>c</sup>; Teresa Vallelonga<sup>d</sup> ;  
Umberto Garagiola<sup>e</sup>; Andrea Merlo<sup>f</sup>

## ABSTRACT

**Objective:** To evaluate reverse-sequencing chewing cycles (RSCC) and their kinematic parameters on both sides before and after correction with the Function Generating Bite (FGB) appliance.

**Materials and Methods:** Forty-seven patients,  $8.3 \pm 1.1$  (mean  $\pm$  SD) years of age, with unilateral posterior crossbite (35 on the right side, 12 on the left side) and 18 age-matched controls ( $9.1 \pm 0.8$  years) were selected for the study from the orthodontic division of the University of Turin, Italy. The crossbite was corrected in all patients using FGB, and mandibular motion was recorded with a kinesiograph K-7 (Myotronics, Tukwila, Wash), during chewing on both sides of a soft and a hard bolus before and after correction.

**Results:** After correction, the percentage of RSCC significantly decreased for soft and hard ( $P < .001$ ) boluses and fell within the normal range for 75% of the patients. The indices of the chewing pattern (closure angle, axis, maximum lateral excursion) significantly improved ( $P < .001$ ), becoming symmetric between sides.

**Conclusions:** The results of this study showed that the functional appliance, FGB, was able to lower the percentage of RSCC significantly, bringing them back to the normal range in 75% of cases, and to improve the kinematic parameters that become symmetric between sides. (*Angle Orthod.* 0000;00:000–000.)

**KEY WORDS:** Crossbite; Malocclusion; Mastication; Chewing pattern; Chewing cycle; Interceptive orthodontics

<sup>a</sup> Researcher, Interdepartmental Research Center (CIR) Dental School, Division of Orthodontics, Department of Surgical Sciences, Turin University, Turin, Italy.

<sup>b</sup> Assistant Professor, School of Dental Medicine, Stony Brook University, Stony Brook, NY, USA.

<sup>c</sup> Postdoctoral student, University of Turin, Turin, Italy.

<sup>d</sup> Postgraduate in Orthodontics, University of Turin, Turin, Italy.

<sup>e</sup> Assistant Professor, Department of Biomedical Surgical and Dental Sciences, Maxillo-Facial and Odontostomatology Unit, Fondazione CàGranda IRCCS Ospedale Maggiore Policlinico, University of Milan, Milan, Italy.

<sup>f</sup> Contract Professor, Motion Analysis Laboratory, Local Health Unit (AUSL) of Reggio Emilia, Department of Rehabilitation, Correggio, Italy.

Corresponding author: Dr Maria Grazia Piacino, Dental School, Department of Surgical Sciences, University of Turin, Via Nizza, 230, 10126 Torino, Italy (e-mail: mpianci@gmail.com)

Accepted: June 2017. Submitted: February 2017.

Published Online: August 3, 2017

© 0000 by The EH Angle Education and Research Foundation, Inc.

## INTRODUCTION

Successful, modern orthodontic therapy considers not only the repositioning of teeth within the dental arches but also the benefits of therapy on masticatory function. Crossbites are very common and readily diagnosed components of malocclusion. Their prevalence ranges in the literature from 8% to 22% of the population. About 50% of crossbites are unilateral posterior crossbites, meaning that one or more teeth in the premolar and/or molar region are involved on one side only of the dental arch.<sup>1,2</sup>

Unilateral posterior crossbites (UPCs) are considered a severe asymmetric and progressive form of malocclusion. There are three critical principles to be considered with UPCs. First, they may appear as early as eruption of the primary molars and may involve the permanent successors at a later stage of development.<sup>3</sup> Second, their origin may be positional (mandibular displacement), dentoalveolar or skeletal, or a

combination of both, always leading to skeletal asymmetries. Third, they are associated with an asymmetry of masticatory function, which influences the motor control of the chewing patterns at an early stage of development of the central nervous system.<sup>3,4</sup>

Patients with a UPC show an increased frequency of reverse-sequencing chewing cycles (RSCC) in the frontal plane, when chewing on the affected side. Reverse chewing cycles,<sup>5</sup> according to Lewin, are defined by reverse direction of closure, narrow pattern, and limited lateral displacement.<sup>1,6</sup> They occur during chewing on the crossbite side only while, on the nonaffected side, the pattern maintains physiological features.<sup>5</sup> This results in compensatory asymmetric function,<sup>1</sup> worsening of unbalance of skeletal growth, neuromuscular structures,<sup>7</sup> and temporomandibular joint over time.<sup>8,9</sup>

The literature shows that the dental correction of UPCs can be obtained with or without the correction of reverse chewing patterns<sup>3,4</sup> depending on therapy and appliance selection. Although most appliances easily correct the dental malocclusion,<sup>4,10</sup> the recovery of masticatory function after dental correction is not easy nor obvious.<sup>3,10</sup> The prevalence of RSCC is a useful indicator of the impairment of masticatory function that is easy to obtain. The literature shows that the Function Generating Bite (FGB) appliance is able to lower the percentage of RSCC with high significance. FGB is a functional appliance characterized by a stainless steel resilient bite plane that prevents the teeth from intercuspal contacts during orthodontic movement.<sup>3</sup> To this end, inputs from the molar mechanoreceptors are important for the reorganization of a new cortical chewing motor network.

Because the RSCC is associated with altered kinematics,<sup>3,5,11</sup> altered pattern morphology, and altered muscular activation, it is interesting to analyze not only the RSCC but also the related kinematic pattern. The hypothesis is that recovery of the RSCC can be obtained after correction with the FGB, but the correction of kinematic parameters may require a longer time to reach stability.

The aim of this study was to evaluate the proportion of abnormal reverse chewing cycles and their kinematic parameters measured before and after correction of UPC with the FGB appliance.

## MATERIALS AND METHODS

Forty-seven children with an average age of  $8.3 \pm 1.1$  years (mean  $\pm$  SD) with UPC (35 on the right side, 12 on the left side) and 18 children,  $9.1 \pm 0.8$  years of age, with normal occlusion were selected for the study from patients presenting for orthodontic evaluation between April 2014 and June 2016. Patients gave written informed consent before entering the study,

which was performed according to the Declaration of Helsinki. The study was approved by the Inter-company Institutional Review Board A.O.U. City of Health and Science of Turin–A.O. Ordine Mauriziano–A.S.L. City of Turin, No. CS/246, 764/2014.

The inclusion criteria were right or left UPC involving three or more posterior teeth in the mixed dentition. The exclusion criteria were the presence of any previous orthodontic therapy, any surgical occlusal cant in the frontal plane, any sign of craniomandibular disorder, or any prosthesis.

A control group was strictly selected for normal occlusion and mixed dentition and was matched with the patient group for age and gender to provide reference normative values.

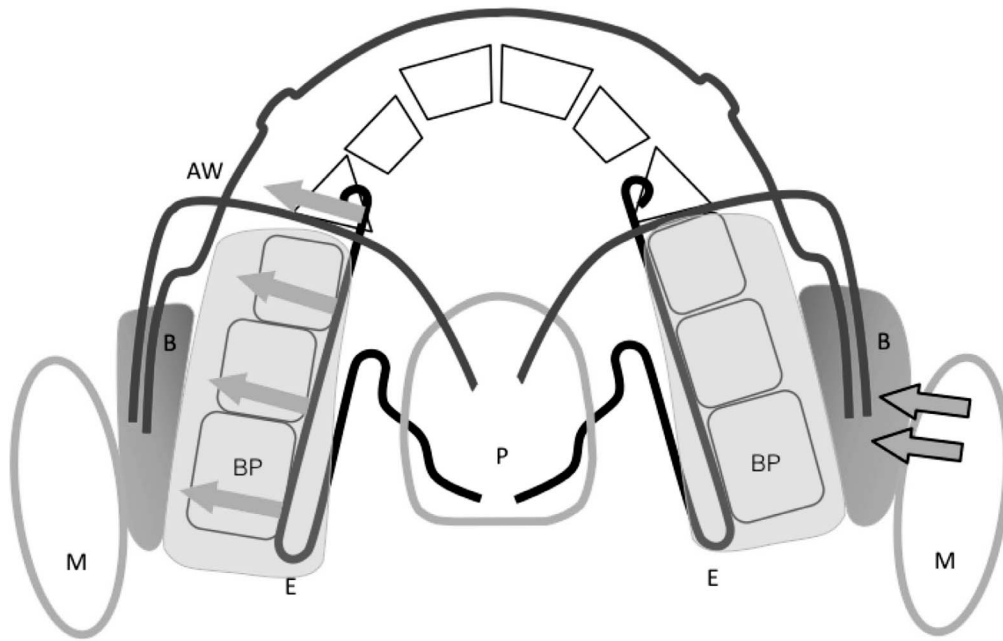
## Appliance

Each patient was treated with the FGB<sup>1,3</sup> functional appliance. The FGB appliance is a functional device, individually wrapped, made of acrylic resin and resilient stainless steel wires and posterior bites. It is characterized by muscle anchorage and activates during swallowing to result in physiological intermittent forces. At the end of treatment, the occlusal plane is leveled, the dental arches are aligned, and the buccal cusps of the upper teeth, which were previously in crossbite, overlap the lower teeth, thus providing the appropriate physiological stimuli from peripheral receptors and proprioceptors for all patients (Figure 1).

The treatment time to achieve occlusal correction in the study group was  $6.2 \pm 1.8$  months, and the retention period before recording the chewing cycles was 5 to 6 months.

## Protocol

Patients underwent the chewing cycle recording protocol at the time of recruitment ( $T_0$ ) and 5 to 6 months after correction with FGB ( $T_1$ ). Children were comfortably seated on a chair. They were asked to fix their eyes on a target (a red beak of a Donald Duck drawing) on the wall, 90 cm directly in front of their seating position, and to avoid movements of the head. Each recording consisted of chewing for a time period of 10 s and was repeated, for each experimental session, three times for mastication on the right side and three times for mastication on the left side, using a soft bolus and a hard bolus. The soft bolus was a piece of chewing gum, and the hard bolus was a wine gum. Boluses had the same size (2 cm in length, 1.2 cm in width, and 0.5 cm in height) but different weights (2 g for the soft bolus and 3 g for the hard bolus) and different puncture forces (0.36 for the soft and 1.85 for the hard bolus). The wine gum was chosen to provide a rubberlike resistance without sticking to the teeth.



**Figure 1.** Function Generating Bite (FGB) appliance characterized by stainless steel, resilient, smooth bite planes; expansion springs; and buccal shields. BP indicates bite planes; AW, arch wires; E, expansion spring; P, palatal plate or button; B, buccal shields (the different thickness between sides allows the asymmetric activation of the contralateral expansion spring when needed); M, masseter.

### Kinematic Analysis

The mandibular motion during chewing was tracked using a kinesiograph (K7-I; Myotronics) that measures jaw movements with an accuracy of 0.1 mm. Multiple sensors (Hall effect) in a lightweight (113 g) array tracked the motion of a tiny magnet attached at the lower interincisal point. The kinesiograph was interfaced with a computer for data storage and subsequent analysis. The kinematic signals were analyzed with custom-made software (Department of Orthodontics and Gnathology, University of Turin, Turin, Italy). The reliability of the recording of the chewing cycles with the kinesiograph has been tested previously.<sup>12</sup> The first and any anomalous cycles characterized by (1) minimum opening smaller than 4 mm, (2) duration shorter than 300 ms, or (3) cycle length shorter than 6 mm were excluded. From each cycle, the following kinematic and temporal indices were extracted: closure angle, axis, maximum lateral excursion, opening amplitude, and opening and closing durations (Figure 2). Indices were computed for each cycle and subsequently averaged over all available cycles recorded for the same side of mastication and bolus type (typically 30–40 cycles). Chewing cycles were divided into nonreverse and reverse, based on the vectorial direction of closure. The closure angle was measured between a straight line obtained by a robust regression procedure on the last part of the curve (from 2.0 to 0.1 mm from the closing point in the vertical direction) and the horizontal line of the side of

mastication. Next, cycles with a closure angle larger than 90° were grouped in the reverse set (Figure 2).<sup>11</sup>

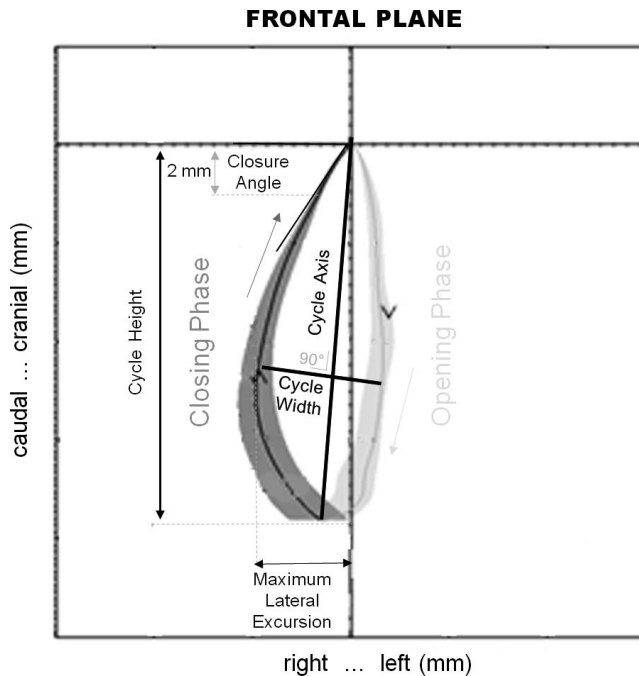
### Statistical Analysis

The indices' mean values and standard deviations were computed and reported to provide literature-comparable results. A nonparametric approach was used for all statistical analyses as normal distribution was not confirmed for all indices' data. Differences between independent means of both reverse-sequencing cycles' proportions and temporal and kinematic indices were assessed by the *U*-Mann test. Mean differences in paired analyses were assessed by the Wilcoxon test. Statistical significance was set at 5%, and power was set at 80% for all tests. Based on sample size, admitted type 1 and type 2 errors, and selected statistical tests, an effect size of 0.53 was required to detect differences between independent means (Mann's test), and an effect size of 0.38 was required to detect differences in paired analyses (Wilcoxon's test). Statistical analyses were performed using Matlab (Mathworks, Natick, Mass).

### RESULTS

The results and statistical significance regarding the prevalence of the RSCC are reported in Table 1 and regarding the kinematic parameters in Table 2.

In healthy subjects, the average rate of RSCC was 3% ± 4% for the soft and hard bolus. The 90th



**Figure 2.** Graphic representation of the kinematic variables described in the text. The solid lines (green: opening; red: closing) represent the average chewing cycle of three trials lasting 10 s each. The light green and light red areas represent the standard deviation over the average cycle.<sup>12</sup>

percentile value of the reverse chewing patterns rate was 10% with both boluses (Table 1). At the time of recruitment, in patients chewing on the crossbite side, the reverse chewing cycle rate was  $60\% \pm 29\%$  for the soft and  $71\% \pm 33\%$  for the hard bolus. Both values were significantly greater than those of the age-matched controls ( $P < .0001$ ; Table 1).

After therapy during chewing on the corrected side (previous crossbite), the reverse chewing pattern rate significantly decreased to  $10\% \pm 13\%$  ( $P < .001$ ) for the soft and  $11\% \pm 12\%$  for the hard bolus ( $P < .001$ ). No statistically significant variations occurred in the reverse chewing pattern rate during chewing on the noncrossbite side, which was  $12\% \pm 20\%$  for both bolus types. Noticeably, for 35 of the 47 patients (75%) the reverse chewing cycle rate fell within the normal 10–90 percentile range 6 months after correction of the malocclusion with FGB (Figure 3).

At baseline, chewing pattern kinematic indices during chewing on the crossbite side were significantly different from those during chewing on the noncrossbite side, and they changed toward their normal reference values after therapy (Table 2; Figure 4). Interestingly, after therapy, the closure angle and maximum lateral excursion on the crossbite side no longer showed differences with the noncrossbite side, thus achieving symmetry of masticatory function. However, they did not reach normal reference values, as the axis values did.

## DISCUSSION

The aim of this study was to evaluate functional outcomes of early interceptive orthodontic therapy of UPCs achieved with the FGB appliance by investigating both the prevalence of RSCC and kinematic parameters.

The results of this study showed that, after orthodontic correction with FGB, the percentage of RSCC significantly decreased and, noticeably for 75% of patients, the RSCC rate fell within the normal 10–90 percentile range. Moreover, the indices of the chewing pattern significantly improved to become symmetric between sides. During chewing on the noncrossbite side, the indices were similar to the controls. These results are in agreement with the literature.<sup>3–6,10,13–15</sup> There are no other reports in the literature demonstrating a significant decrease of reverse-sequencing chewing patterns after crossbite correction with other devices. In this study, the FGB appliance successfully corrected the malocclusion and recovered masticatory function symmetry. The stainless steel bite planes of the appliance disengaged the mandible, protected the teeth from intercusp contact during orthodontic movement (Figure 1), and controlled the static and dynamic posture of the mandible in three planes of space. They leveled the occlusal plane and aligned the upper and lower arches simultaneously. Moreover, as shown in Figure 1, it is possible to activate the FGB in an asymmetrical way by thickening the buccal shield opposite to the crossbite side. This is a very important option when treating an asymmetric malocclusion such as UPC. All

**Table 1.** Average Rate of Reverse-Sequencing Chewing Cycles (RSCC) in Subjects With a Unilateral Posterior Crossbite Malocclusion Before/After Treatment While Deliberately Chewing on the Crossbite and Noncrossbite Side

Chewing Side	Before Therapy		After Therapy (6 mo)		Controls
	Crossbite	Contralateral	Crossbite	Contralateral	
Soft bolus	$60\% \pm 29\%^*$	$13\% \pm 18\%^{**}$	$10\% \pm 13\%^{***,***}$	$12\% \pm 20\%^{**}$	$3\% \pm 4\%$
Hard bolus	$71\% \pm 33\%^*$	$11\% \pm 12\%^{**}$	$11\% \pm 12\%^{***,***}$	$12\% \pm 20\%^{**}$	$3\% \pm 4\%$

\* Statistically different from controls,  $P < .001$ .

\*\* Statistically different from controls,  $P < .05$ .

\*\*\* Statistically lower than before therapy,  $P < .001$ .



**Table 2.** Kinematic and Temporal Indices of the Chewing Cycle During Deliberate Sided Mastication (Crossbite Side and Contralateral Side) With Both a Soft and a Hard Bolus, Before and 6 Months After Therapy with FGB<sup>a</sup>

Chewing Side	Before Therapy		After Therapy (6 mo)		Controls
	Crossbite	Contralateral	Crossbite	Contralateral	
Closure angle, °					
Soft bolus	95 ± 23*,**	61 ± 19**,****	67 ± 13*,***	66 ± 13*	55 ± 12
Hard bolus	101 ± 24*,**	59 ± 20**,****	69 ± 11**,****	69 ± 12*	47 ± 17
Cycle axis, °					
Soft bolus	84 ± 9*,**	74 ± 10**	79 ± 7	79 ± 9	75 ± 5
Hard bolus	86 ± 9*,**	77 ± 9**	82 ± 7****	81 ± 8	77 ± 9
Maximum lateral excursion, mm					
Soft bolus	3 ± 1**,**	5 ± 2**	4 ± 1****,*****	4 ± 2	5 ± 2
Hard bolus	3 ± 1**,**	5 ± 2**	4 ± 2****	4 ± 2	6 ± 2
Opening amplitude, mm					
Soft bolus	13 ± 3	13 ± 3	14 ± 3	14 ± 3	14 ± 4
Hard bolus	15 ± 4	15 ± 4	16 ± 3	16 ± 3	15 ± 4
Cycle opening duration, s					
Soft bolus	0.23 ± 0.05	0.22 ± 0.05	0.24 ± 0.05	0.24 ± 0.05	0.22 ± 0.04
Hard bolus	0.23 ± 0.06	0.23 ± 0.05	0.23 ± 0.06	0.23 ± 0.06	0.23 ± 0.05
Cycle closing duration, s					
Soft bolus	0.36 ± 0.06	0.34 ± 0.05	0.34 ± 0.06	0.34 ± 0.05	0.34 ± 0.05
Hard bolus	0.35 ± 0.06	0.35 ± 0.06	0.35 ± 0.06	0.35 ± 0.05	0.34 ± 0.06

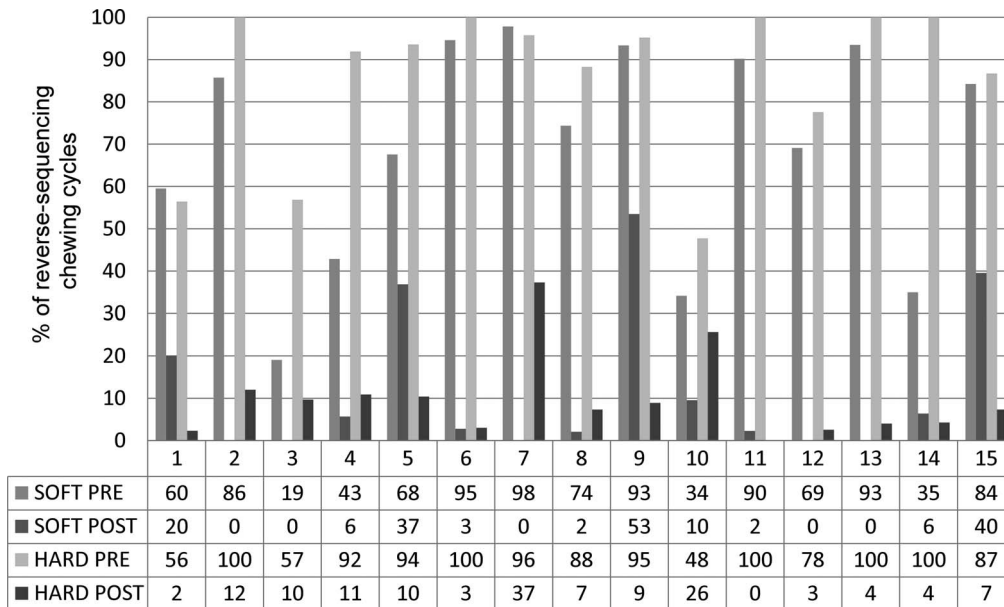
<sup>a</sup> See text for further details. After therapy, values approached their normal reference values with a recovery in symmetry.

- \* Statistically different from controls, *P* < .001.
- \*\* Statistically different from contralateral side, *P* < .001.
- \*\*\* Statistically different than before therapy, *P* < .001.
- \*\*\*\* Statistically different from controls, *P* < .05.
- \*\*\*\*\* Statistically different from contralateral side, *P* < .05.
- \*\*\*\*\* Statistically different than before therapy *P* < .05.

components of the appliance have been studied in depth, evaluated over time with the aim to recover the physiology of masticatory function.<sup>11</sup>

Six months of retention appeared to be adequate to correct the reverse chewing cycles and to improve the kinematic parameters significantly so that they became

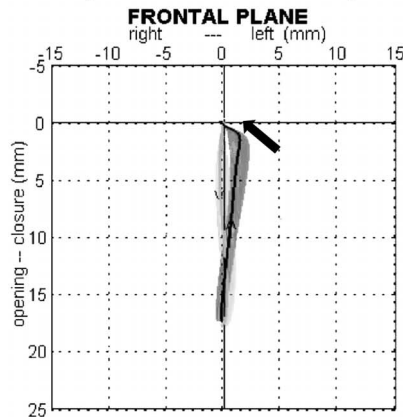
symmetric between sides. The kinematic indices improved were the closure angle that became less vertical, the axis of the cycle that became symmetric between sides, and the width between the opening and closing tracings that became wider (Figures 2 and 4). These kinematic parameters improved toward a higher



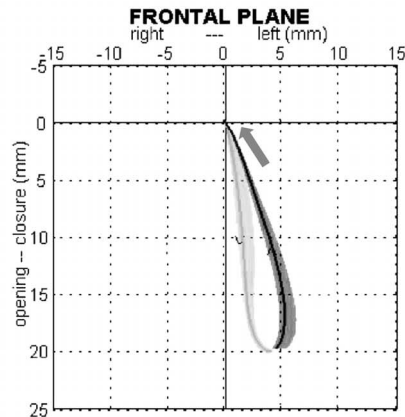
**Figure 3.** Percentage of reverse-sequencing chewing cycles before and after therapy during chewing soft and hard boluses of the first 15 patients.

# BEFORE THERAPY

## RIGHT CHEWING (Crossbite side)

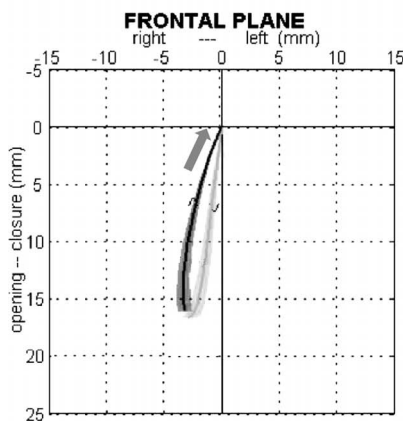


## LEFT CHEWING

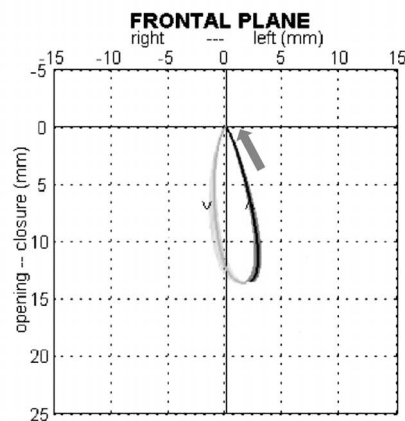


# AFTER THERAPY

## RIGHT CHEWING



## LEFT CHEWING



**Figure 4.** Masticatory pattern of patients during chewing deliberately on the crossbite side and on the contralateral side, before and after therapy. The solid lines (green: opening; red: closing) represent the average chewing cycle of three trials lasting 10 s each. The light green and light red areas represent the standard deviation over the average cycle.<sup>12</sup> Before therapy, the direction of closure during chewing was altered on the crossbite side only (red arrow). After therapy, the direction of closure was restored, specular and symmetric between sides (blue arrows).

efficiency of the chewing cycles, as described by Lewin.<sup>6,16</sup>

Nevertheless, the closure angle and the width during chewing on the crossbite side did not reach the reference normative range. This is important from a clinical point of view and may indicate that a period of 6 months' retention after the UPC correction might be not enough to obtain a full and stable functional recovery, even though the dental aspects seemed to be corrected and stable. Because UPC develops during eruption of the primary dentition, it has a powerful influence on the developing central pattern generator in the brainstem, establishing the reverse sequence type

of chewing pattern that then requires time and continuous physiological functional input to improve kinematics.<sup>4,17</sup> What is really needed for a stable correction of a UPC is the reprogramming of the chewing motor control, and this is possible with repeated physiological stimuli over time. When this aim is not achieved, the risk of relapse and impaired growth remains high. The type of appliance used is relevant because the functional retention period over time requires use of a device that is able to allow physiologic growth and function to occur, thus avoiding traumatic constraint of the dental arches.<sup>4</sup> This can easily be obtained using an FGB<sup>1</sup> appliance during the

night, to maximize the benefits of early orthodontic therapy for growing patients.

Future studies are necessary with a longer period of retention time with FGB, to evaluate long-term follow-up of masticatory function and to detect patients who are at risk for relapse of the malocclusion.

## CONCLUSION

- The results of this study showed that the FGB functional appliance was able to lower the percentage of RSCC significantly, bringing them back to the normal range in 75% of cases, and improved kinematic parameters that became symmetric between sides.

## REFERENCES

1. Piacino MG, Kyrkanides S. *Understanding Masticatory Function in Unilateral Crossbites*. Ames, Ia: John Wiley & Sons; 2016.
2. Harrison JE, Ashby D. Orthodontic treatment for posterior crossbites. *Cochrane Database Syst Rev*. 2001;(1): CD000979.
3. Piacino MG, Talpone F, Dalmaso P, Debernardi C, Lewin A, Bracco P. Reverse-sequencing chewing patterns before and after treatment of children with a unilateral posterior crossbite. *Eur J Orthod*. 2006;28:480–484.
4. Throckmorton GS, Buschang PH, Hayasaki H, Pinto AS. Changes in the masticatory cycle following treatment of posterior unilateral crossbite in children. *Am J Orthod Dentofacial Orthop*. 2001;120:521–529.
5. Piacino MG, Farina D, Talpone F, Merlo A, Bracco P. Muscular activation during reverse and non-reverse chewing cycles in unilateral posterior crossbite. *Eur J Oral Sci*. 2009;117:122–128.
6. Lewin A. *Electrognathographics: Atlas of Diagnostic Procedures and Interpretation*. Berlin: Quintessence; 1985.
7. Veli I, Uysal T, Ozer T, Ucar FI, Eruz M. Mandibular asymmetry in unilateral and bilateral posterior crossbite patients using cone-beam computed tomography. *Angle Orthod*. 2011;81:966–974.
8. Thilander B, Bjerklind K. Posterior crossbite and temporomandibular disorders (TMDs): need for orthodontic treatment? *Eur J Orthod*. 2012;34:667–673.
9. Thilander B, Rubio G, Pena L, de Mayorga C. Prevalence of temporomandibular dysfunction and its association with malocclusion in children and adolescents: an epidemiologic study related to specified stages of dental development. *Angle Orthod*. 2002;72:146–154.
10. Ben-Bassat Y, Yaffe A, Brin I, Freeman J, Ehrlich Y. Functional and morphological-occlusal aspects in children treated for unilateral posterior cross-bite. *Eur J Orthod*. 1993;15:57–63.
11. Piacino MG, Falla D, Merlo A, et al. Effects of therapy on masseter activity and chewing kinematics in patients with unilateral posterior crossbite. *Arch Oral Biol*. 2016;67:61–67.
12. Piacino MG, Bracco P, Vallelonga T, Merlo A, Farina D. Effect of bolus hardness on the chewing pattern and activation of masticatory muscles in subjects with normal dental occlusion. *J Electromyogr Kinesiol*. 2008;18:931–937.
13. Brin I, Ben-Bassat Y, Blustein Y, et al. Skeletal and functional effects of treatment for unilateral posterior crossbite. *Am J Orthod Dentofacial Orthop*. 1996;109:173–179.
14. Sever E, Marion L, Ovsenik M. Relationship between masticatory cycle morphology and unilateral crossbite in the primary dentition. *Eur J Orthod*. 2011;33:620–627.
15. Venancio F, Alarcon JA, Lenguas L, Kassem M, Martin C. Mandibular kinematic changes after unilateral cross-bite with lateral shift correction. *J Oral Rehabil*. 2014;41:723–729.
16. Wilding RJ, Lewin A. The determination of optimal human jaw movements based on their association with chewing performance. *Arch Oral Biol*. 1994;39:333–343.
17. Pinto AS, Buschang PH, Throckmorton GS, Chen P. Morphological and positional asymmetries of young children with functional unilateral posterior crossbite. *Am J Orthod Dentofacial Orthop*. 2001;120:513–520.